

Candidate name: _____

Department of
Emergency Medicine

Princess Alexandra Hospital

**FELLOWSHIP TRIAL EXAMINATION
2018.1**

WRITTEN EXAMINATION

SHORT ANSWER QUESTIONS

**PROPS
BOOKLET**

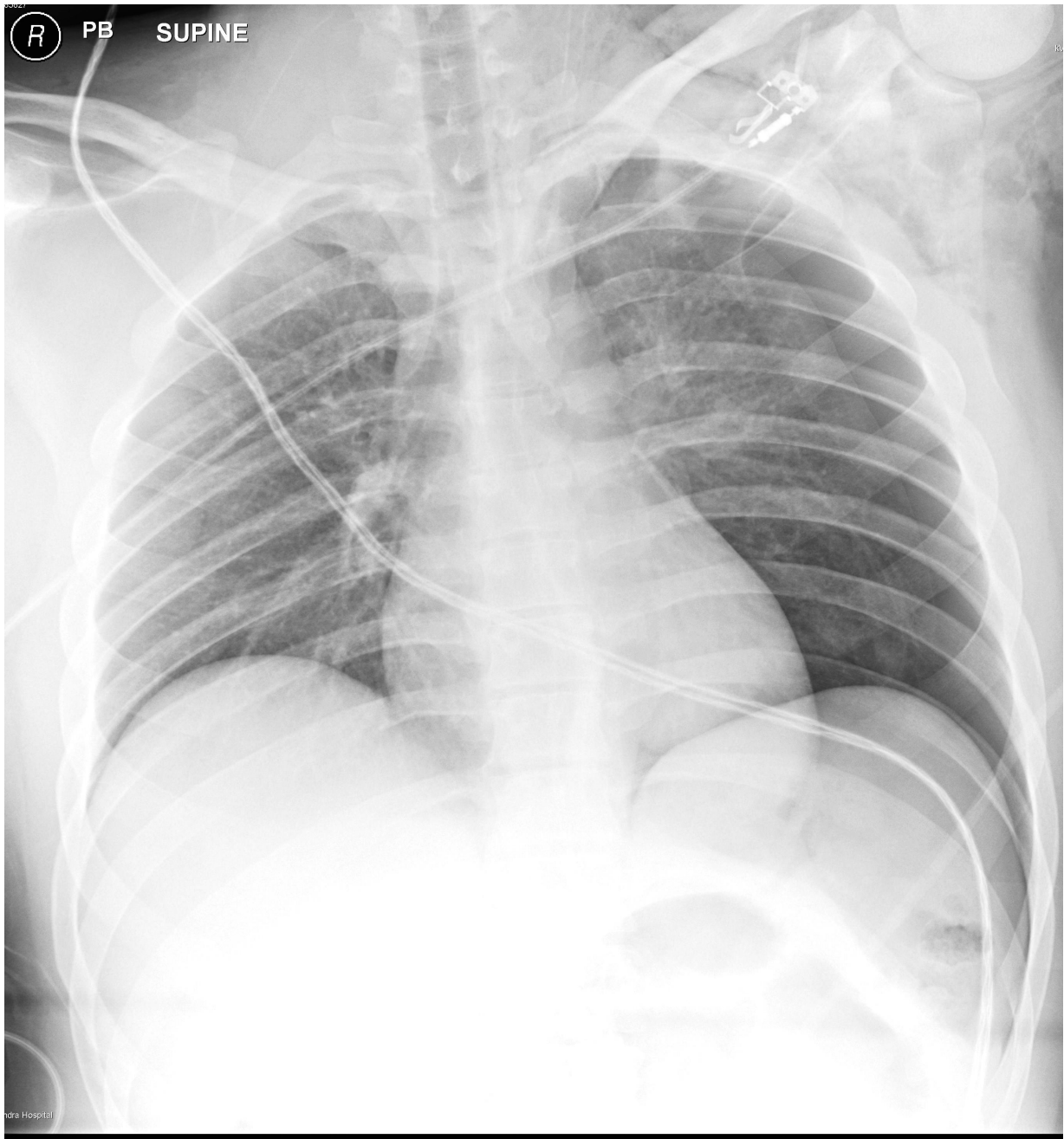
Candidate initials: _____

Candidate initials: _____

Q1 (12 min)

The ambulance service has called to alert you about the impending arrival of a critically unwell patient. You will be receiving a 25 year old man who has been stabbed once to the left side of his anterior chest with a large knife.

Upon arrival, a chest x-ray has been performed. The x-ray is provided **BELOW**.



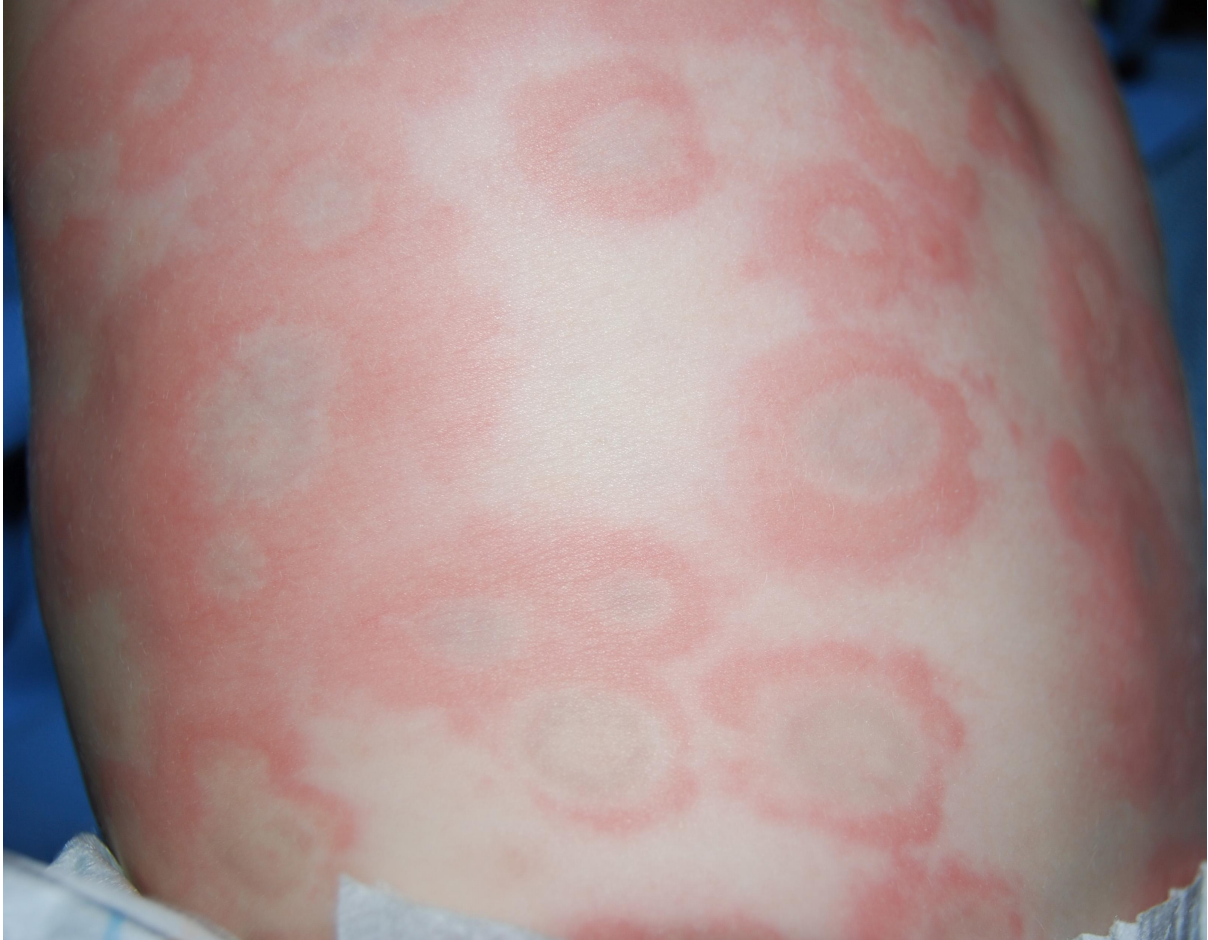This paper is property of the Princess Alexandra Hospital Emergency Department and should not be distributed or published in any way without written permission

Candidate initials: _____

Q4

A 2 year old girl has been brought to the ED with a rash over her torso.

A clinical image is provided **BELOW**.

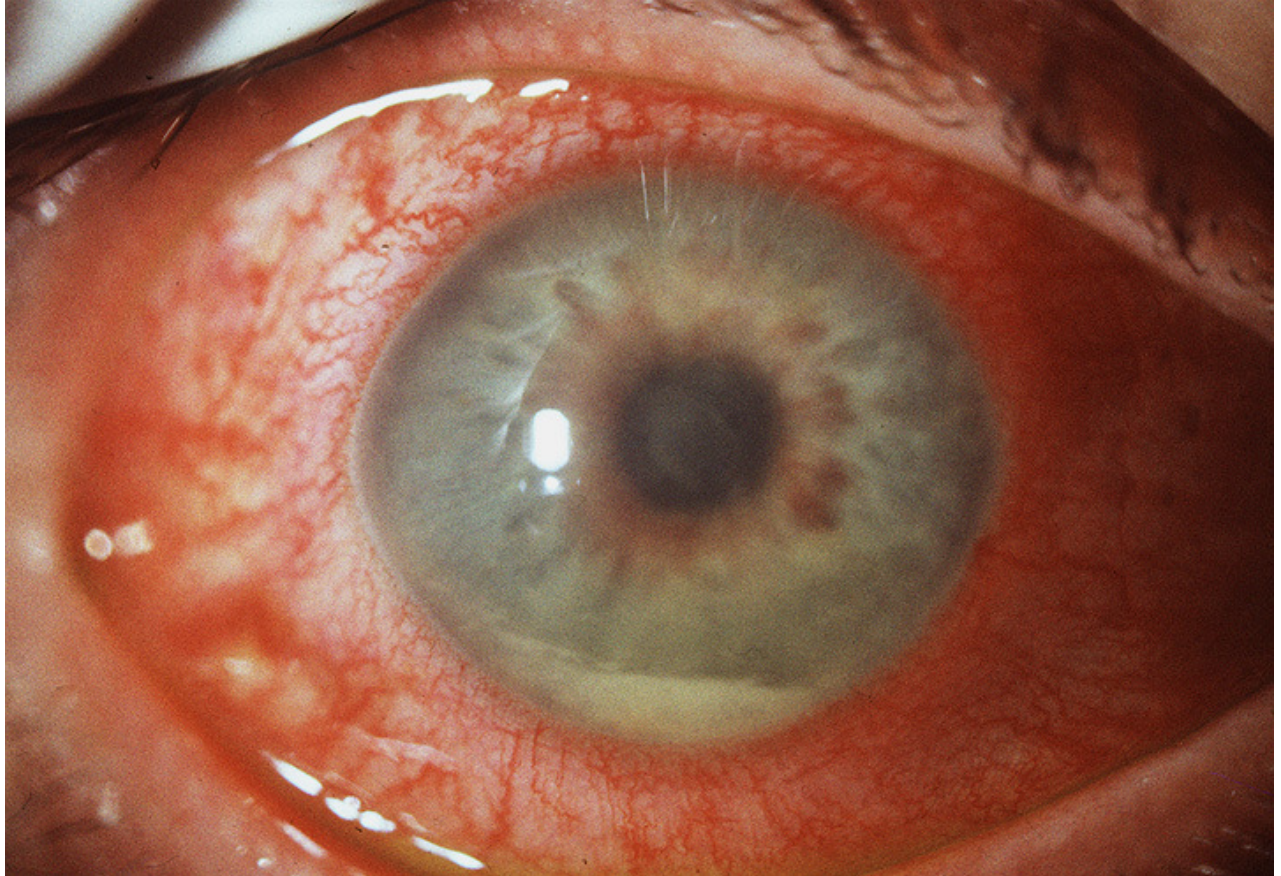


Candidate initials: _____

Q7

A 35 year old man has presented to the ED with a painful, red right eye for the past 2 days.

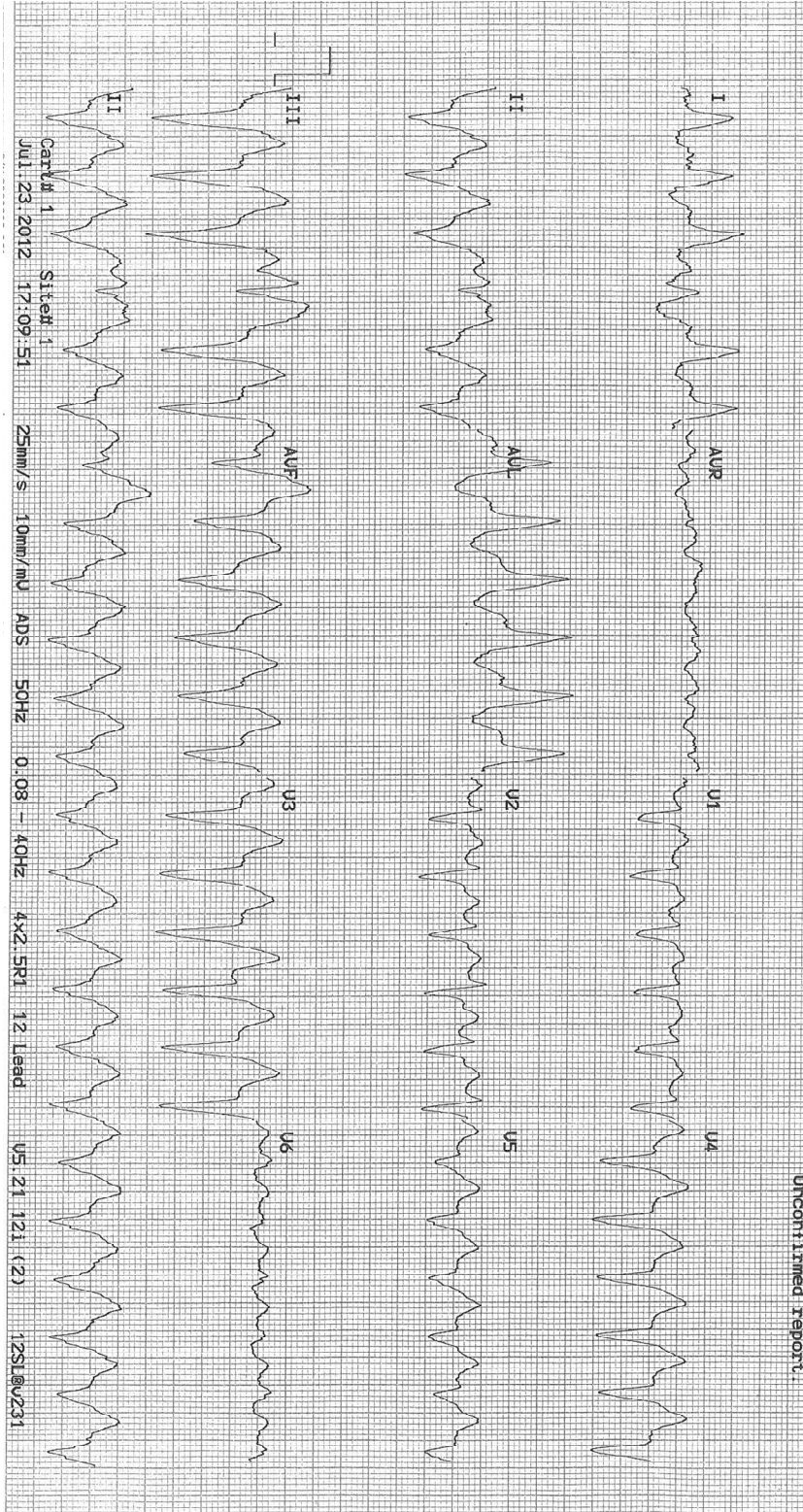
A clinical photo is provided **BELOW**.



Q8

A 70 year old man has been brought to the ED with chest pain and dizziness.

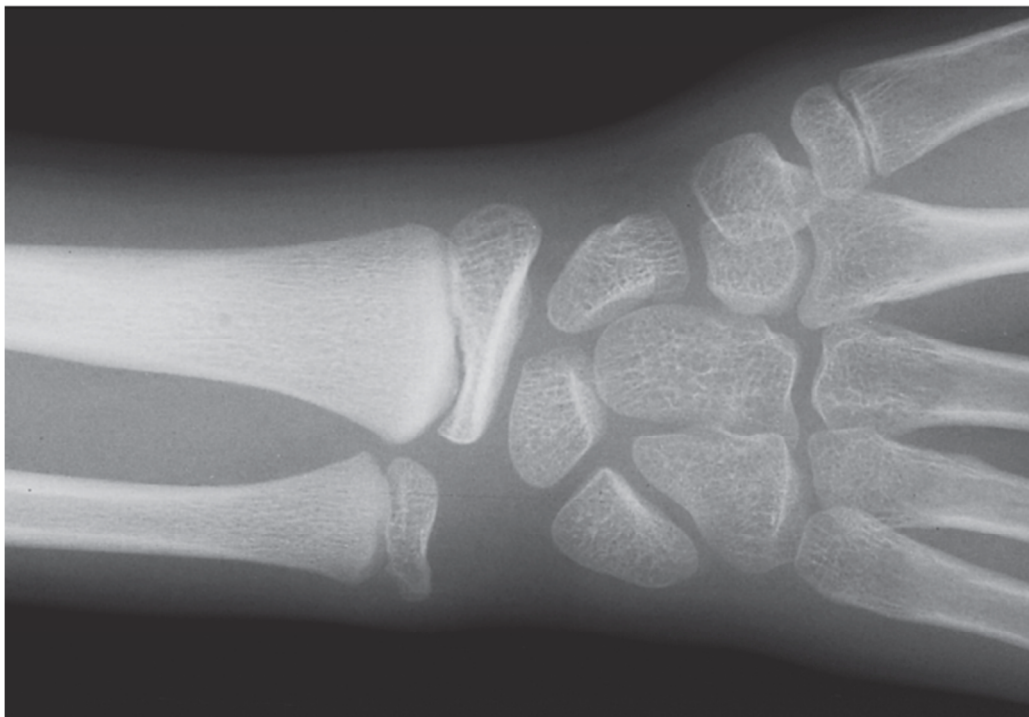
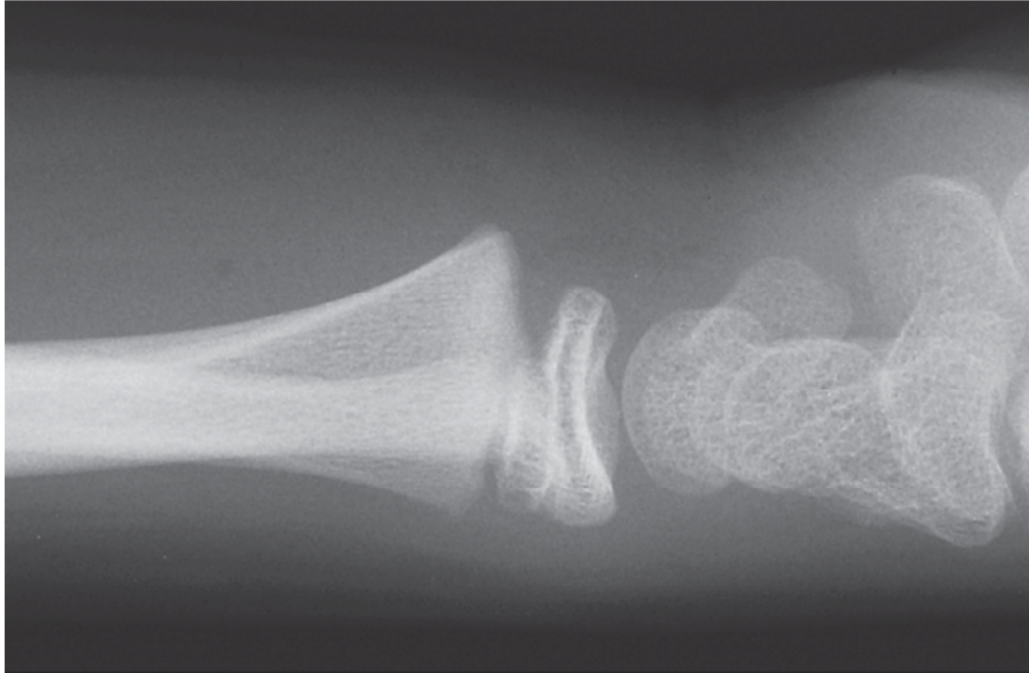
His ECG is provided **BELOW**.



Q9

A 9 year old boy has presented with a painful left wrist after falling off a swing in the playground.

His x-ray is provided **BELOW**.

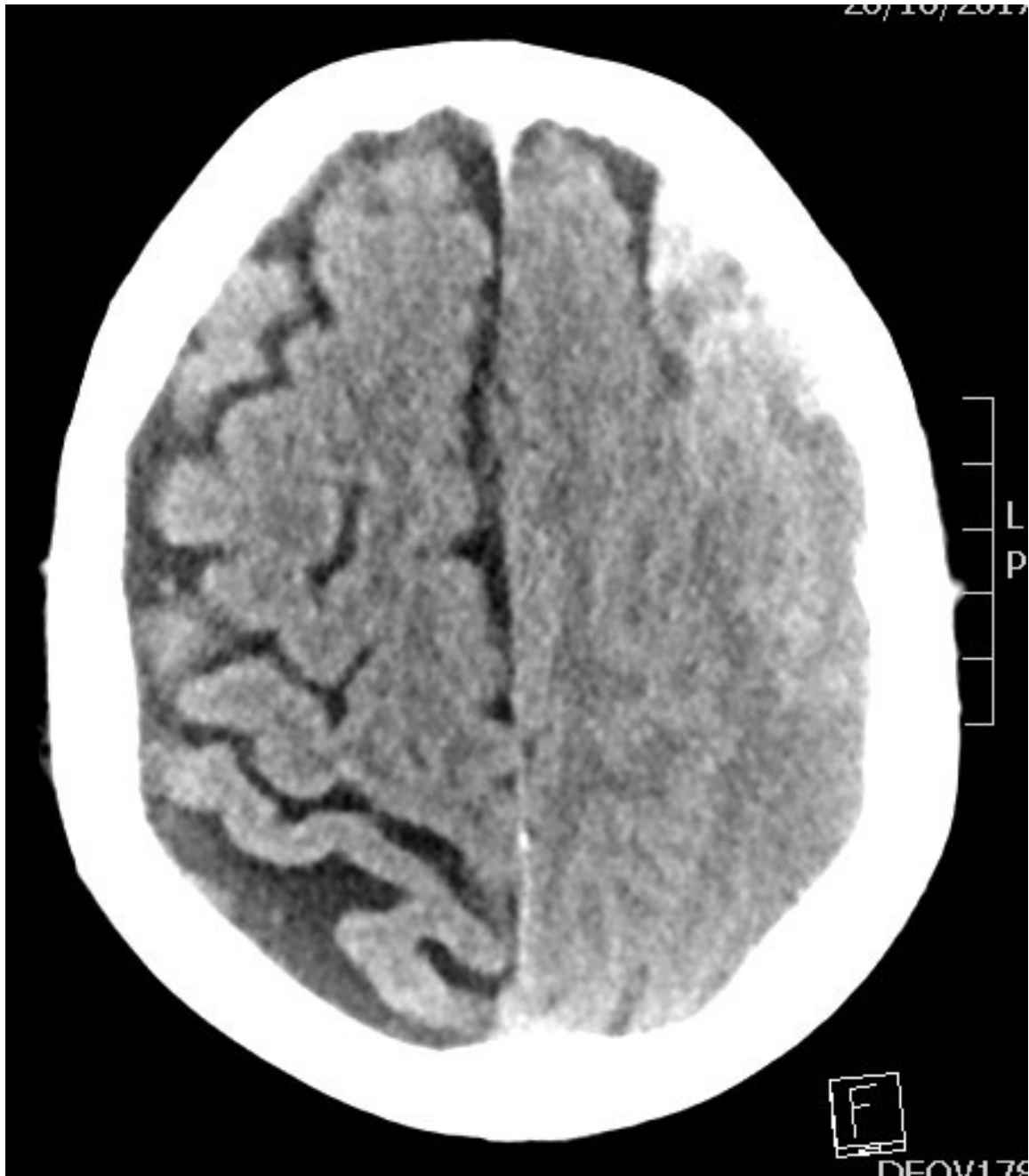

Candidate initials: _____

Q10 (9 min)

A 65 year old woman has been brought to the ED after striking her head when falling down some stairs at her home.

A CT scan of her head is provided **BELOW**.

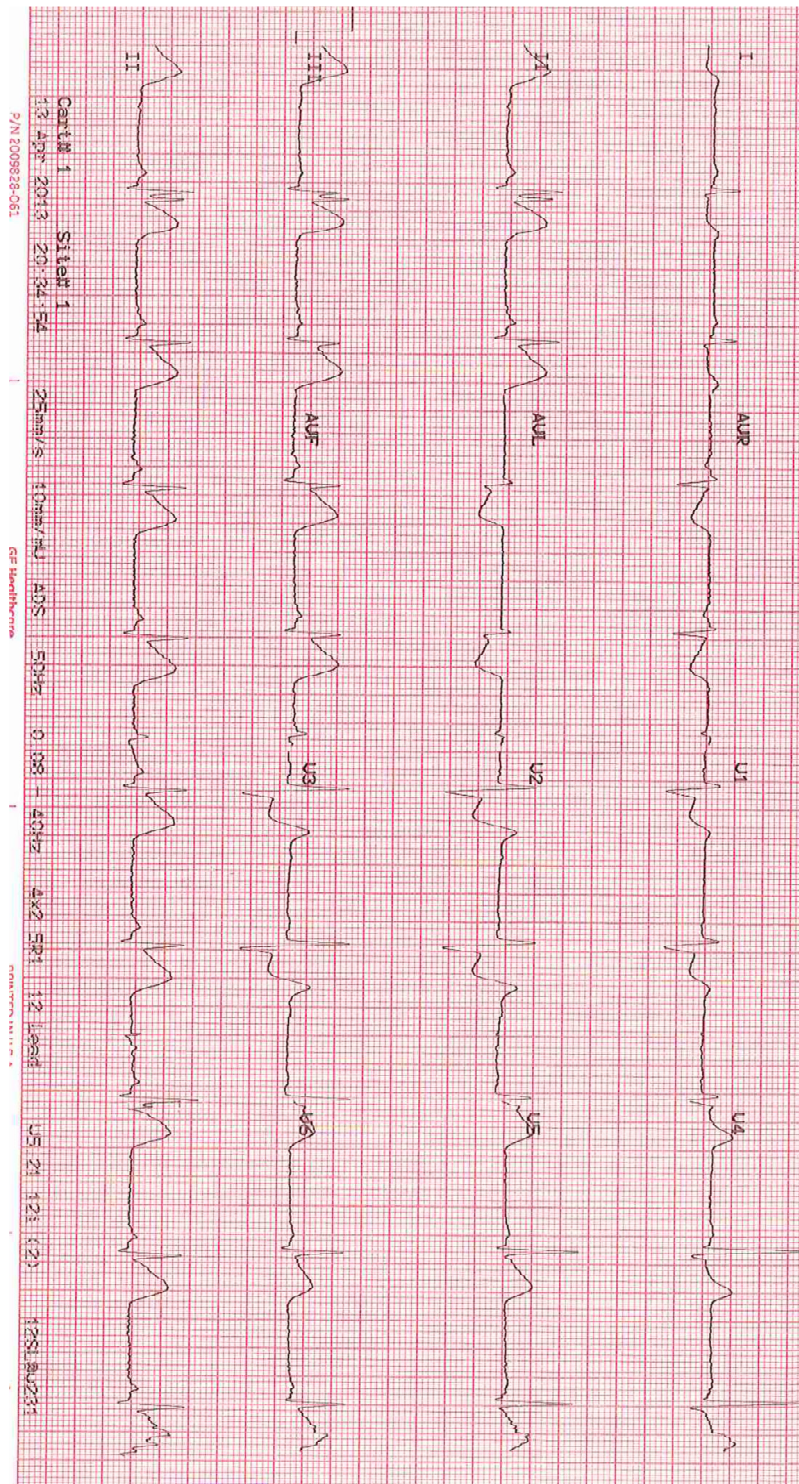


Q11 (9min)

A 55 year old man suffering from a myocardial infarction has been retrieved from a rural hospital. He was treated with aspirin, heparin and intravenous morphine in appropriate doses at the rural ED. He was given tenecteplase 1 hour and 45 minutes ago.

On arrival to your ED, he looks pale and sweaty and is complaining of severe chest pain.

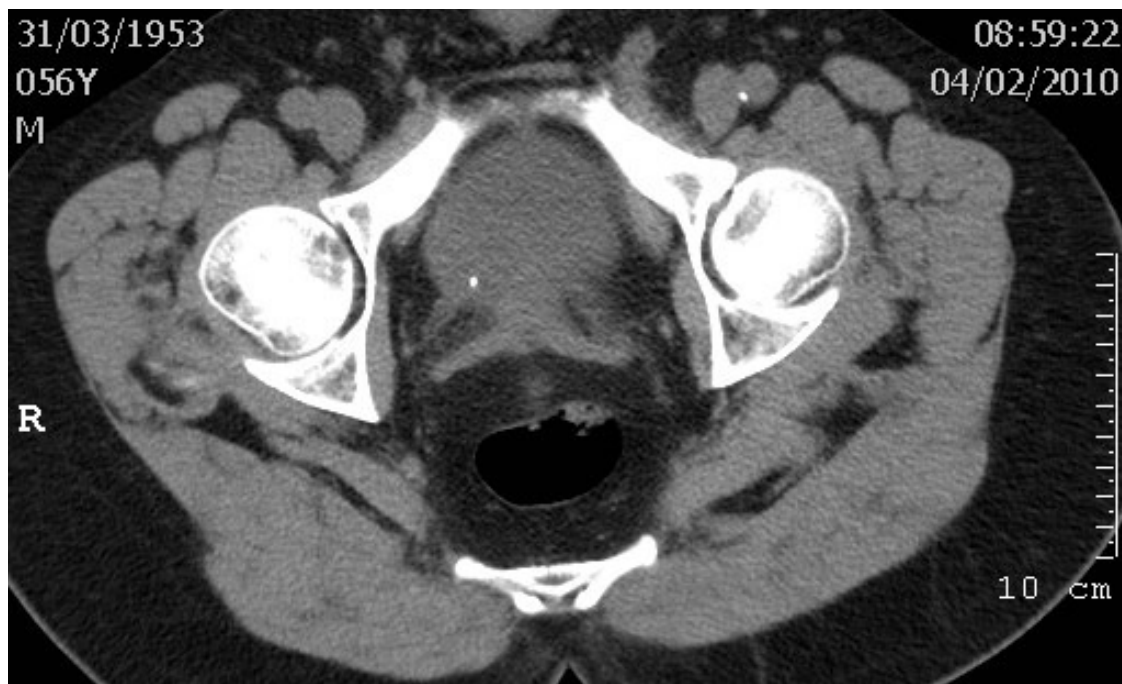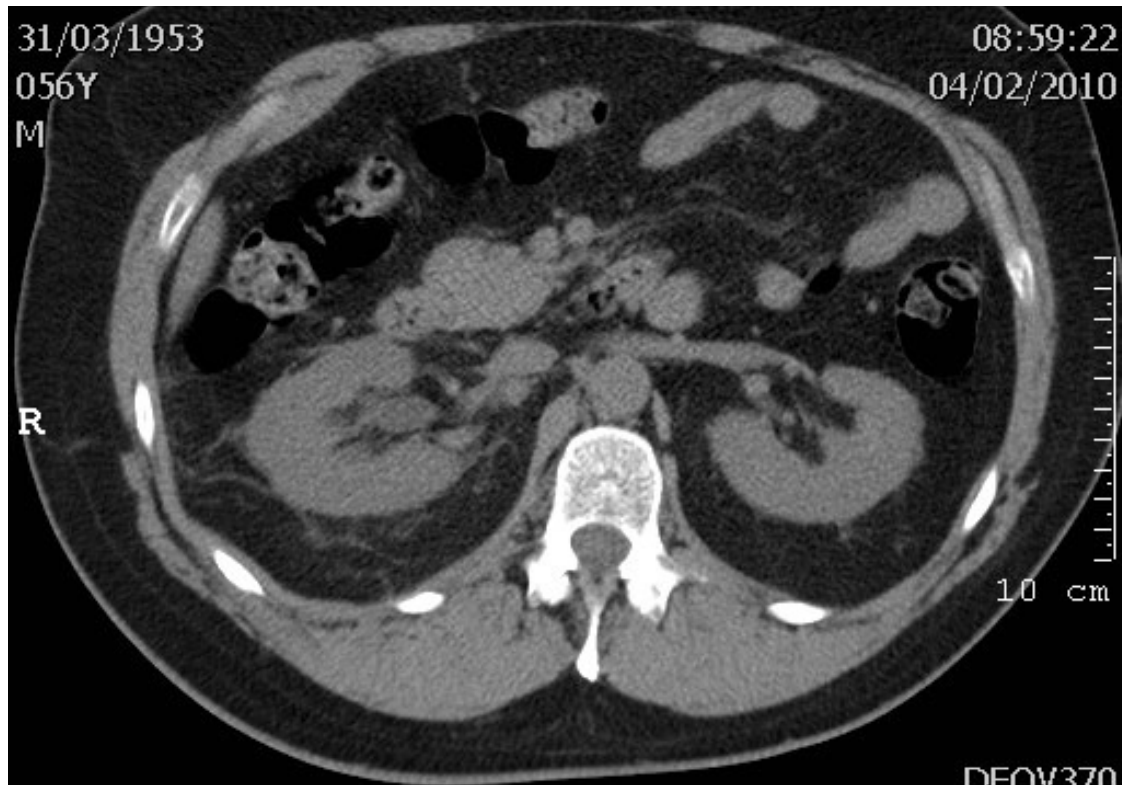His ECG on arrival to your ED is provided **BELOW**.



Q13

A 56 year old man has presented with severe right sided flank pain.

A CT scan has been performed. Two slices (non-contiguous) are provided **BELOW**.



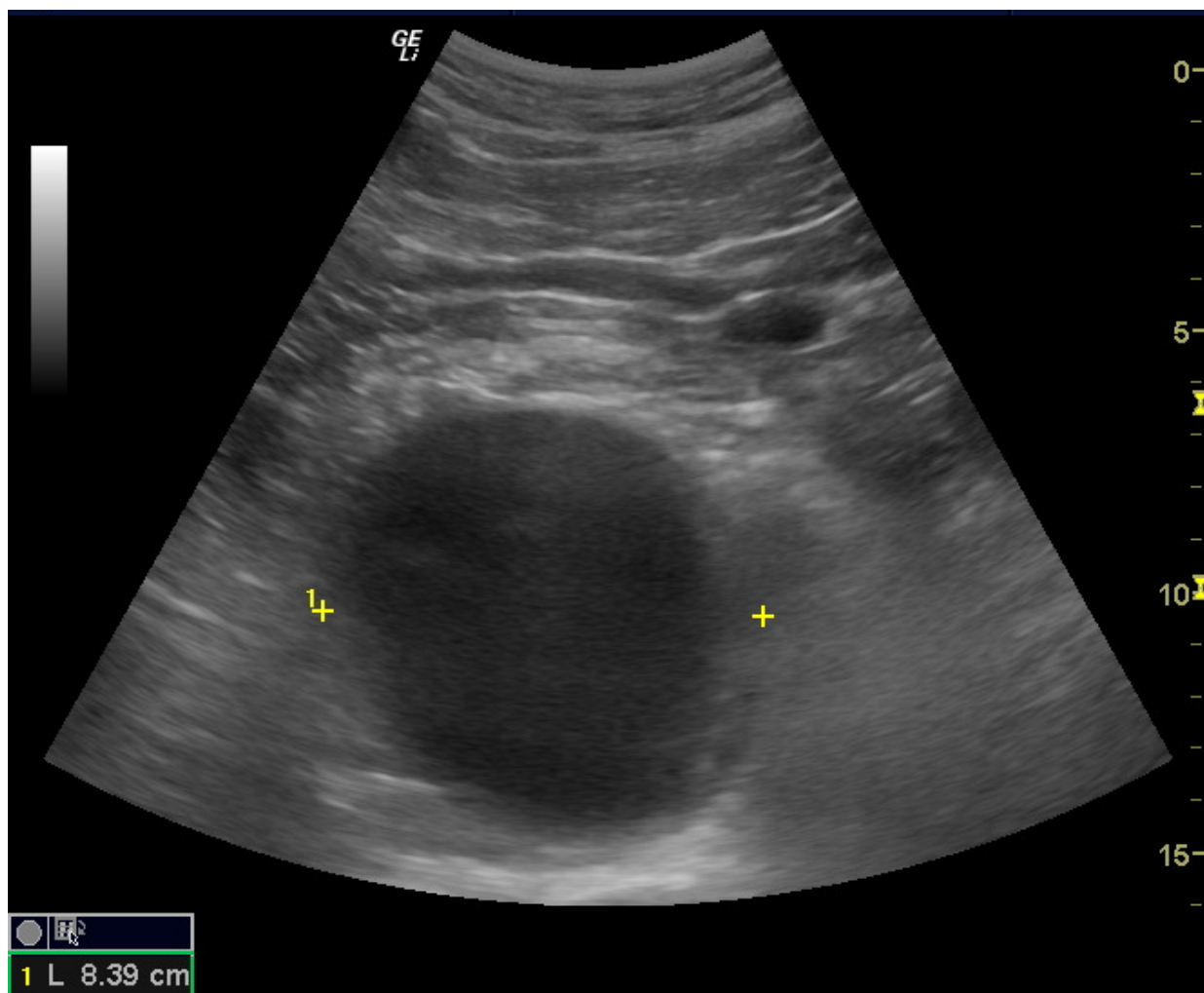
Candidate initials: _____

Q15

A 75 year old woman has collapsed while doing her shopping.

On arrival to the ED, she is complaining of severe abdominal pain radiating to her back.

An image from a bedside USS of her abdomen is provided **BELOW**.



Q16

A 3 year old girl has been brought to the ED with a headache and fever.

You are concerned about the possibility of bacterial meningitis.

A lumbar puncture has been performed. The results are given **BELOW**.

CSF analysis

			<u>Reference range</u>
WBC	1220	/uL	(<5)
Polymorphs		95%	
Mononuclear cells		5%	
RBC	40		(<5)
Glucose	1.1	mmol/L	(2.5 – 4.4)
Protein	312	mg/dL	(<40)

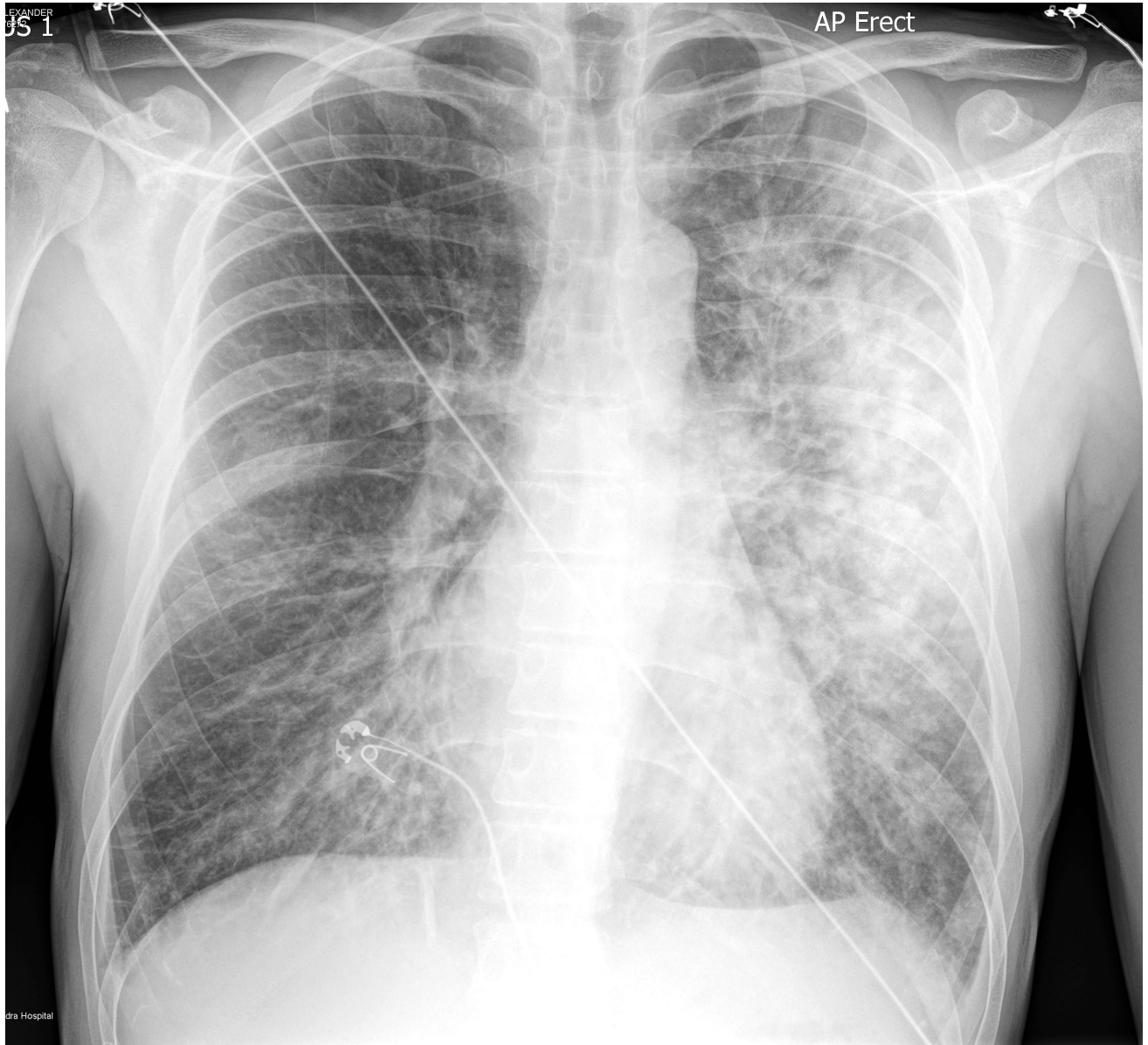Candidate initials: _____

Q19

A 35 year old man has presented to the ED with 24 hours of progressive breathlessness.

On assessment, he has increased work of breathing and is hypoxic on room air.

A chest x-ray is provided **BELOW**.



This paper is property of the Princess Alexandra Hospital Emergency Department and should not be distributed or published in any way without written permission

Q19 (continued)

An arterial blood gas taken from the patient is provided **BELOW**.

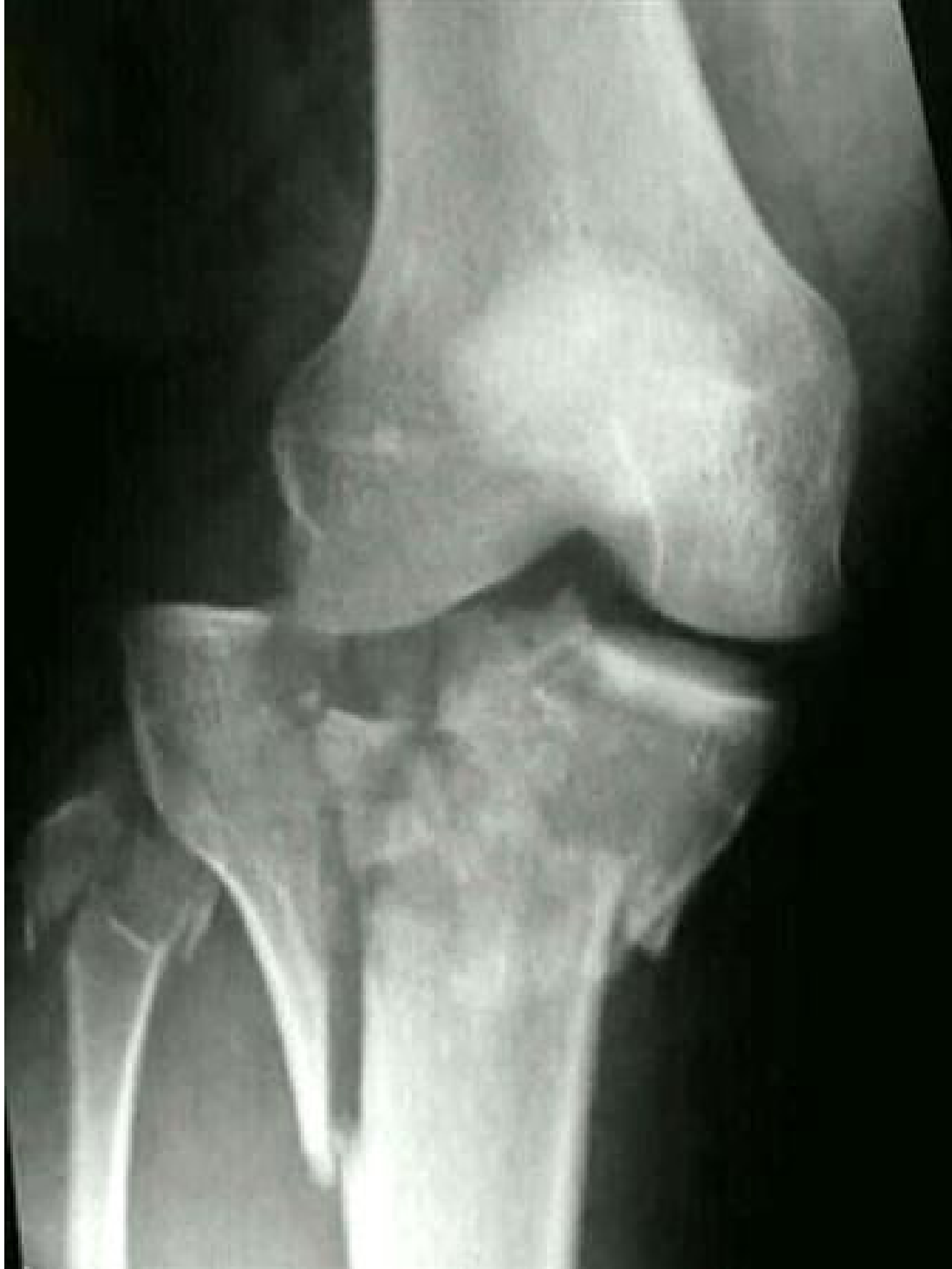FiO₂ 1.0 (15 L O₂ via non-rebreather mask)

			<u>Reference range</u>
pH	7.11		(7.35- 7.45)
pCO ₂	61	mmHg	(35 - 45)
pO ₂	158	mmHg	
HCO ₃ ⁻	19	mmol/L	(22-28)
Base Excess	-12	mmol/L	(-3 - +3)
Na ⁺	141	mmol/L	(135 - 145)
K ⁺	3.8	mmol/L	(3.5 – 5.0)
Cl ⁻	105	mmol/L	(95 – 110)
Glucose	10.7	mmol/L	(3.0 - 7.0)

Q22

A 44 year old woman has been struck by a car while walking across a road. She has sustained an isolated right knee injury.

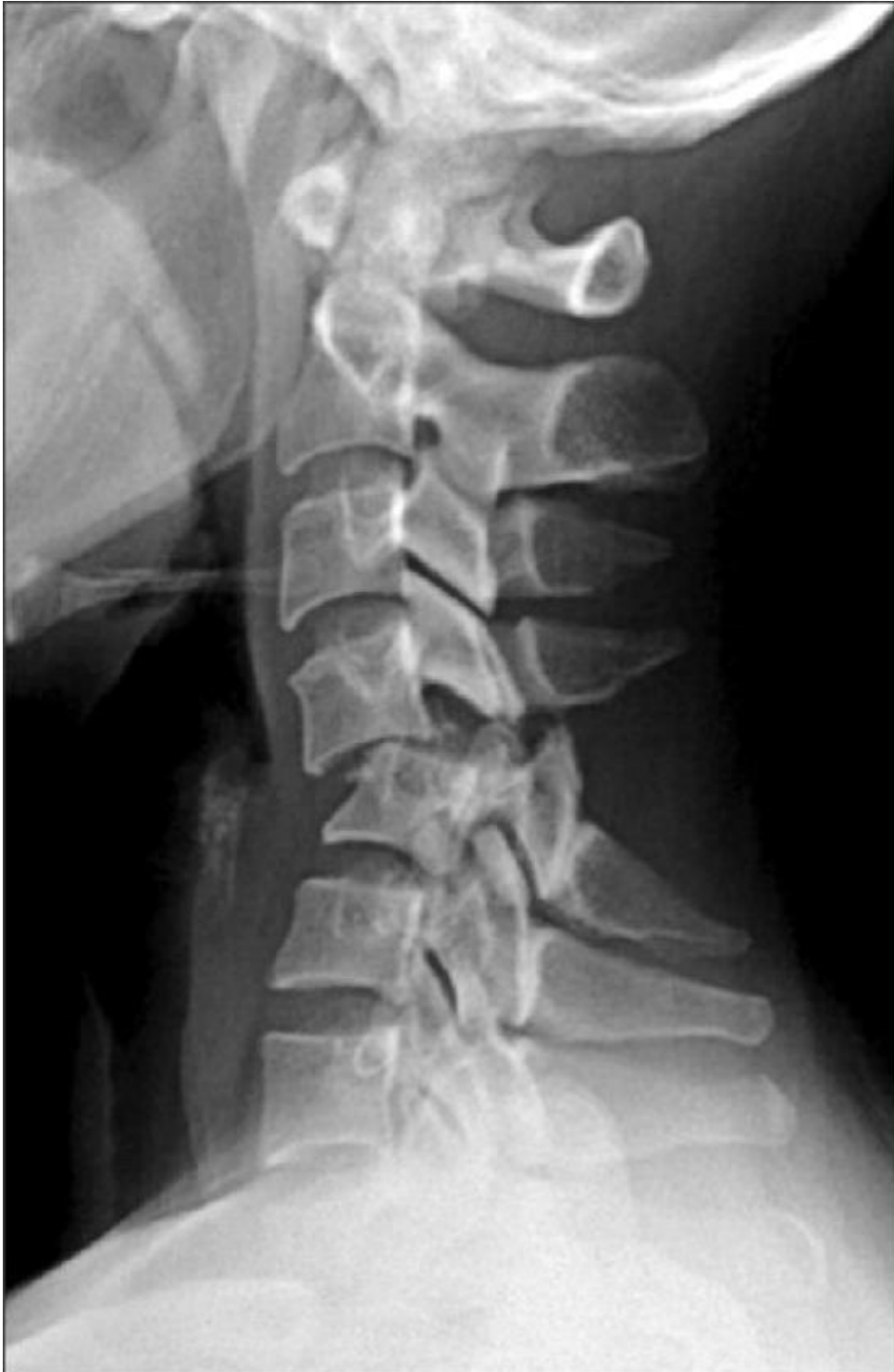An AP x-ray of her right knee is provided **BELOW**.



Q25

A 24 year old man has been brought to the ED after diving in to a shallow pool while intoxicated.

His cervical spine x-ray is provided **BELOW**.



Q26

A 42 year old man has presented to the ED with abdominal pain and jaundice.

His liver function tests are provided **BELOW**.

Bili	85	umol/L	(<20)
Bili (conj.)	10	umol/L	(<4)
AST	750	U/L	(<35)
ALT	850	U/L	(<45)
GGT	200	U/L	(<55)
ALP	350	U/L	(30 – 110)
Albumin	29	g/L	(35 – 50)